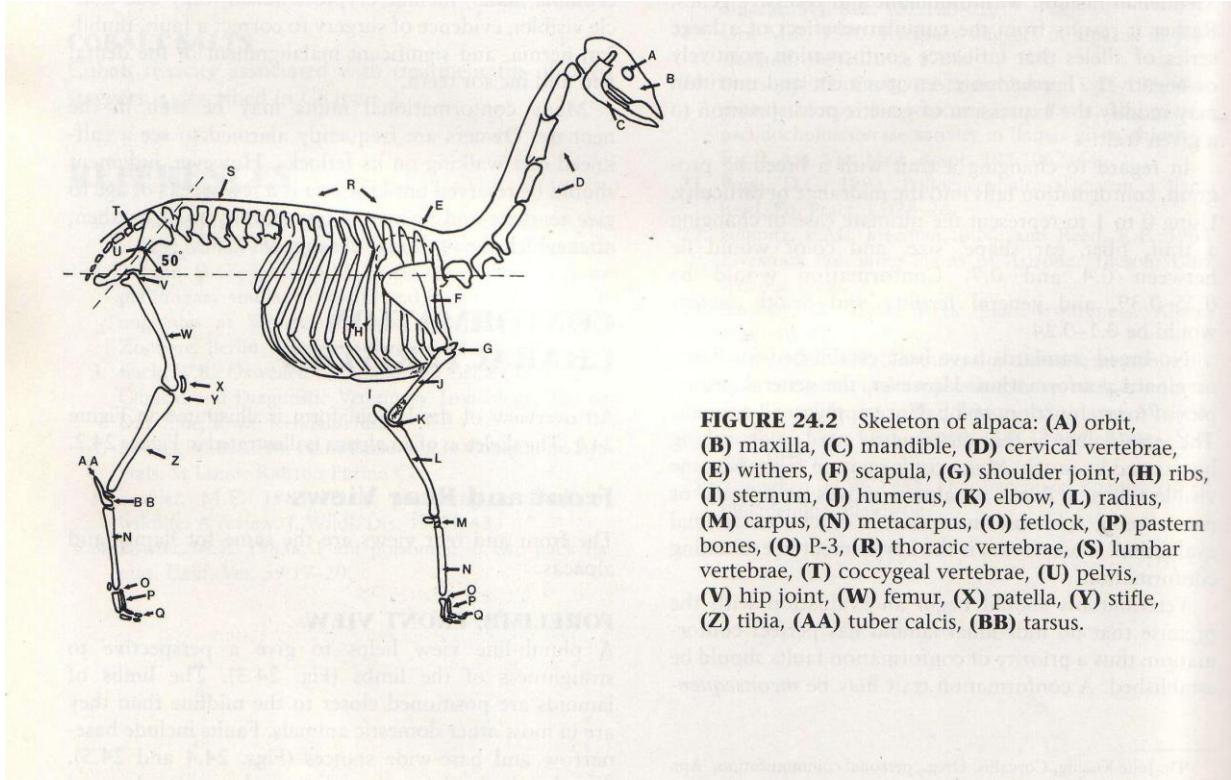
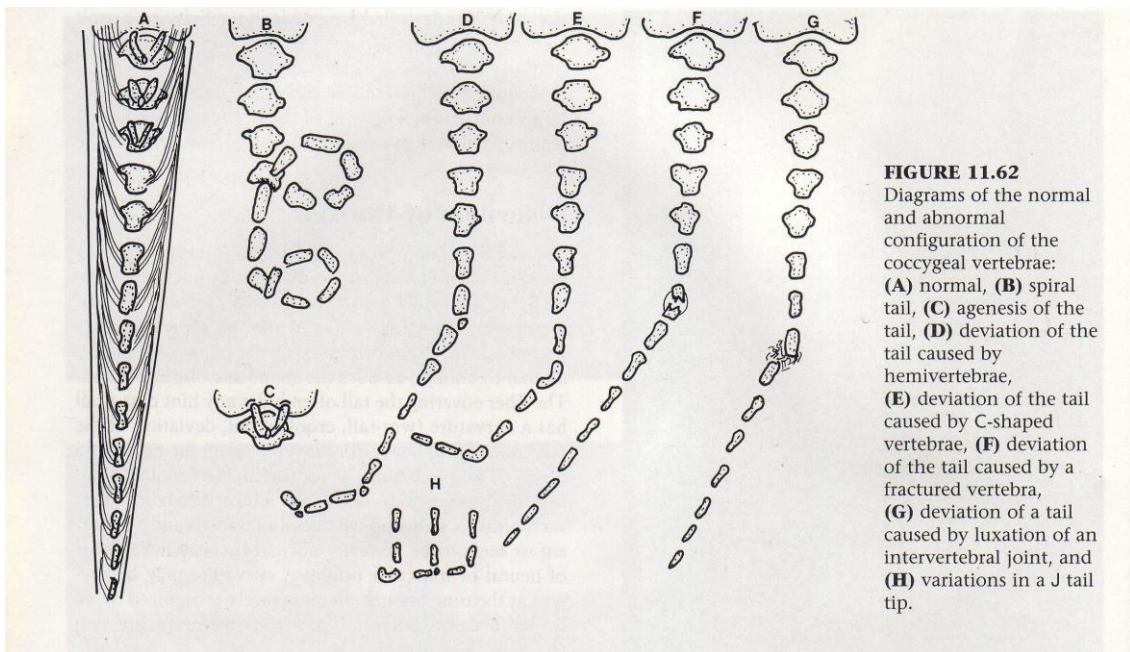


ALPACA BODY



ALPACA TAIL



ALPACA LEGS

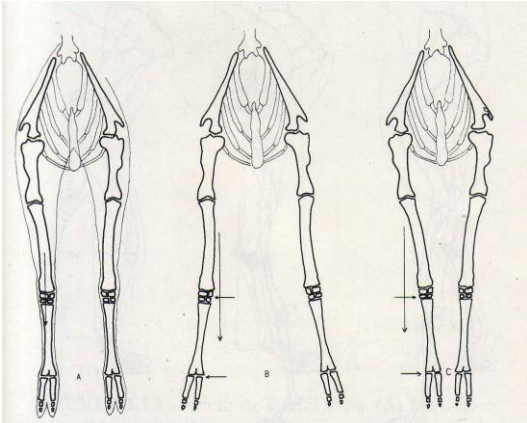


FIGURE 24.4 Forelimb, front view: (A) normal, (B) base wide, (C) base narrow.

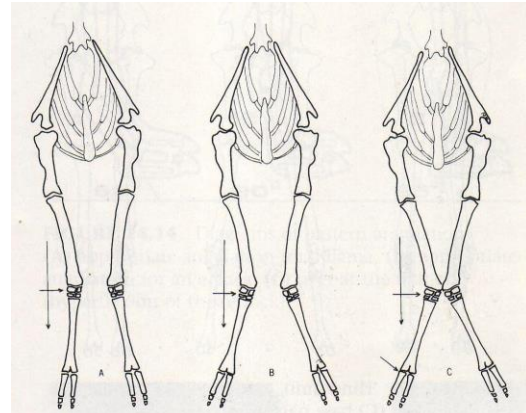


FIGURE 24.6 Angular limb deformity: (A-C) degrees of carpal valgus.

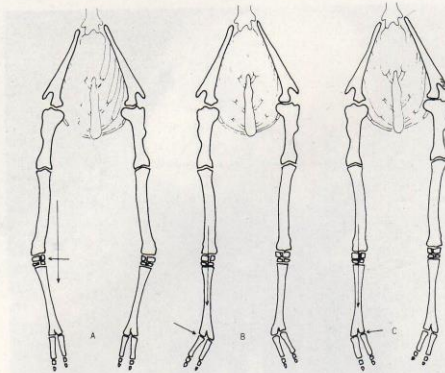


FIGURE 24.7 Forelimb, front view: (A) carpal varus, (B) angular deformity of fetlock (splayed), (C) angular deformity of fetlock (pigeon-toes).

LEG PROFILE

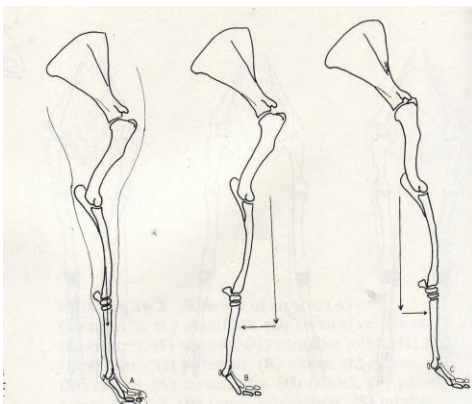


FIGURE 24.10 Forelimb, lateral view: (A) normal, (B) camped behind, (C) camped forward.

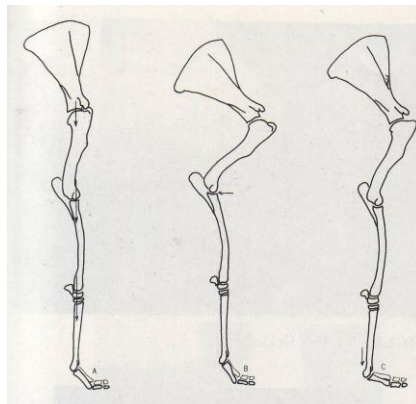


FIGURE 24.11 Forelimb, lateral view: (A) straight or post leg, (B) excessive angulation of shoulder, (C) hyperextension of the fetlock.

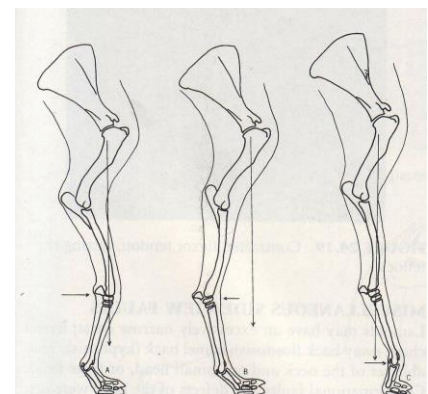
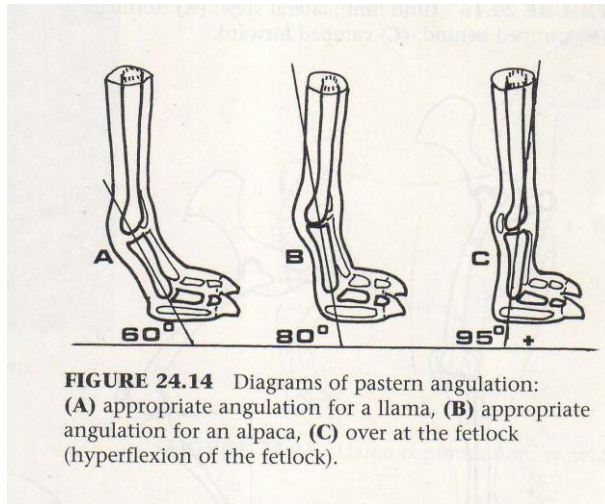


FIGURE 24.12 Forelimb, lateral view: (A) buck-knee, (B) calf-knee, (C) contracted flexor tendons of fetlock.

ALPACA FEET



The Suri Network would like to thank Dr. Murray Fowler for his permission to use the figures in the Suri Breed Standard. All figures used were from the reference listed below:

Fowler, ME: Medicine and Surgery of South American Camelids. Ames, Iowa: Iowa State University Press 292, 518-521; 1998.